

AQUEOUS HUMOR DYNAMICS

BY DR. RAHUL

MODERATOR:DR. DHAMANKAR

ANATOMY

- UVEAL TRACT CONSIST OF
- IRIS
- CILIARY BODY
- CHOROID

IRIS

- CILIARY ZONE
- PUPILLARY ZONE
- MICROSCOPIC
- ANTERIOR LIMITING LAYER
- STROMA
- ANTERIOR PIGMENTED EPITHELIAL LAYER
- POSTERIOR PIGMENTED EPITHELIAL LAYER

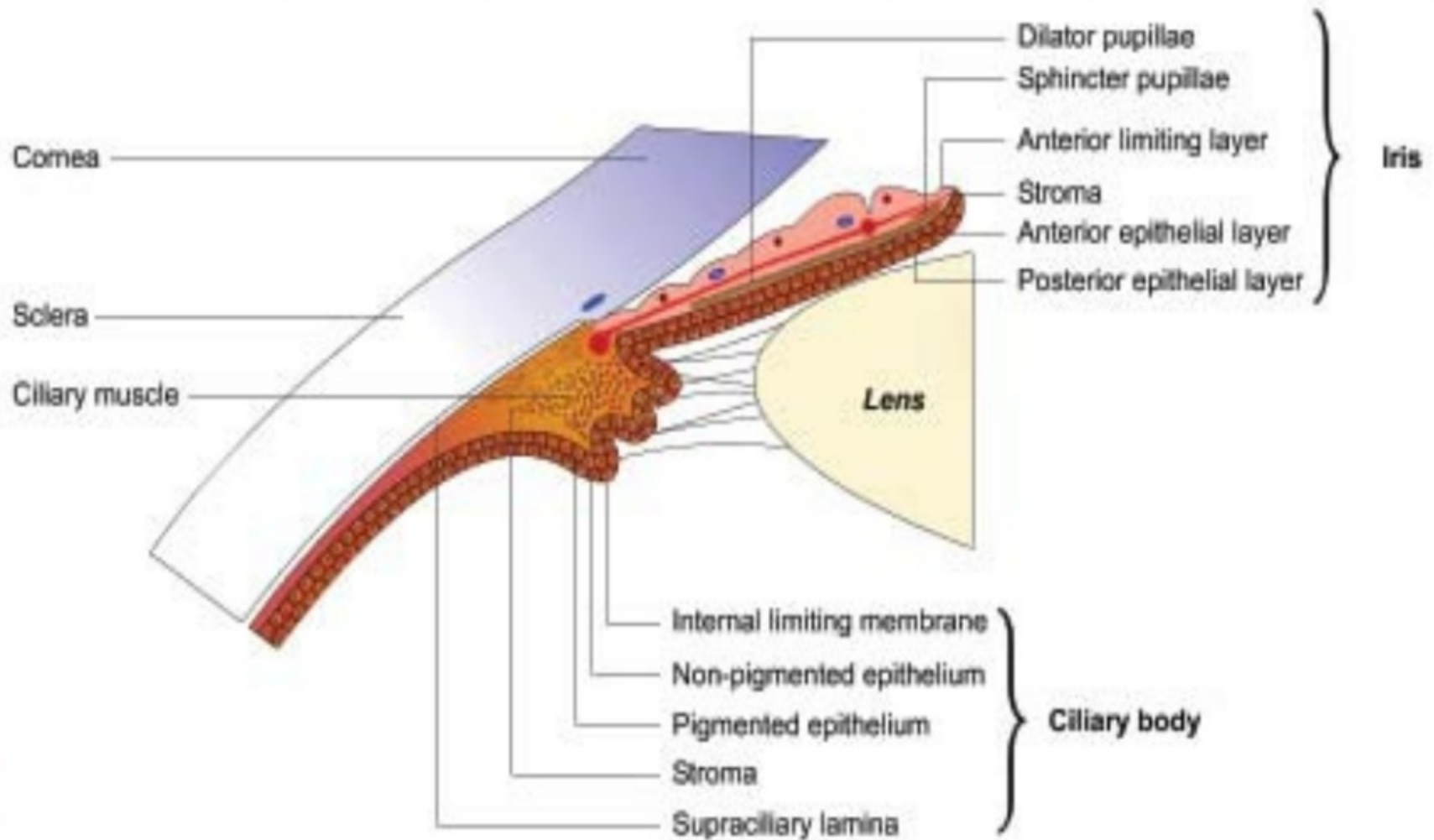
CILIARY BODY

- FORWARD CONTINUATION OF CHOROID
- ANTERIOR PART HAVING FINGER LIKE CILIARY PROCESSES CALLED PARS PLICATA
- POSTERIOR SMOOTH PART PARS PLANA

● CILIARY PROCESSES

- THESE ARE FINGER LIKE PROJECTIONS
- 70-80 IN NUMBER
- 2 MM LONG AND 0.5 MM IN D
- WHITE IN COLOUR
- EACH PROCESS LINED BY 2 LAYERS OF EPITHELIAL CELLS
- IT CONTAINS BLOOD VESSELS AND LOOSE CONNECTIVE TISSUE
- SITE OF AQUEOUS PRODUCTION

ANATOMY



Ciliary epithelium

- Nonpigmented - inner layer, adjacent to aqueous in the posterior chamber,
- consisting of columnar cells (cuboidal in pars plana).
- Intercellular tight junctions (zonulae occludens) form major element of blood-aqueous barrier.
- Tips or crests of nonpigmented ciliary epithelia are site of active secretion,



● hence numerous mitochondria, rough
● endoplasmic reticulum, pinocytic

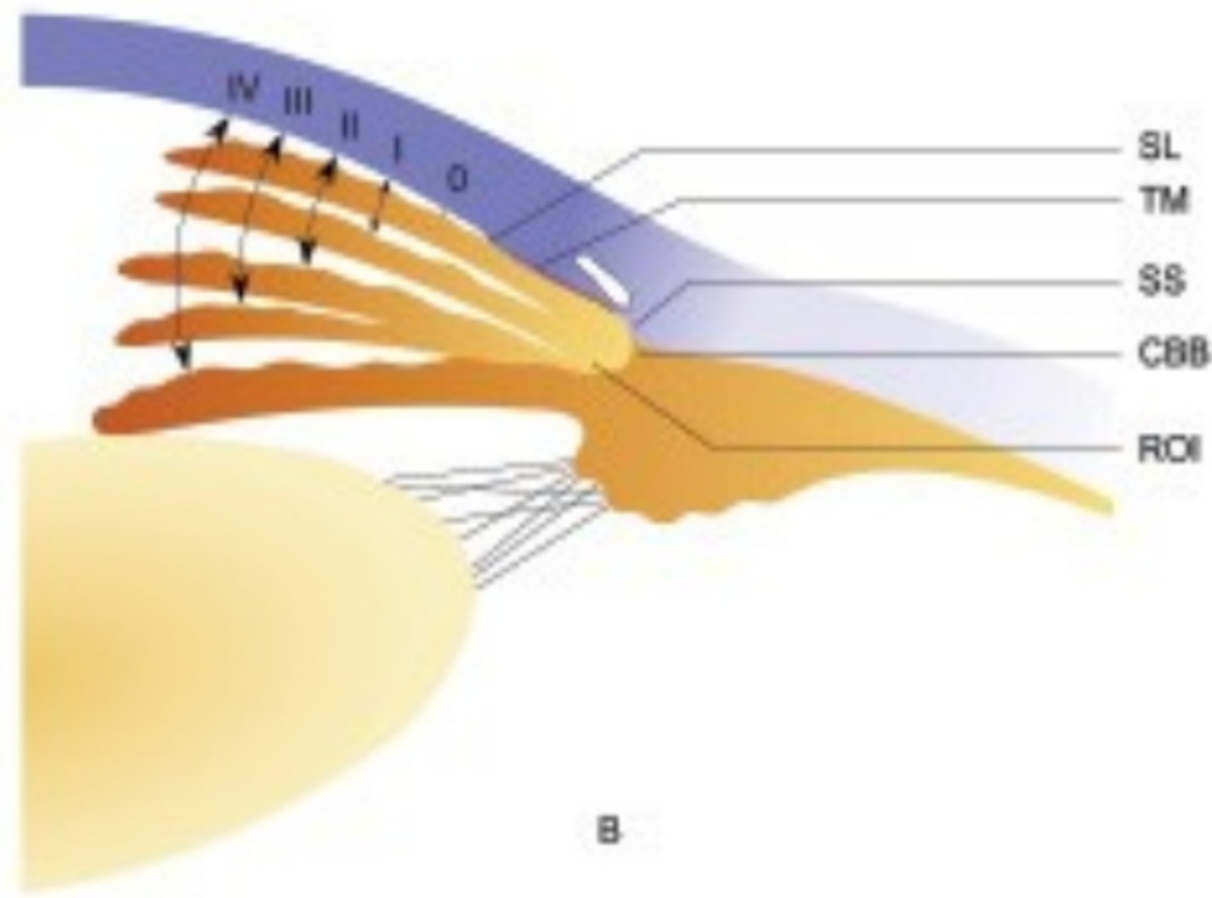
Angle of anterior chamber

- Clinically angle structures can be visualized by gonioscopic examination
- Starting from posterior to anterior
 - 1)Ciliary band
 - 2)Scleral spur
 - 3)Trabecular meshwork
 - 4)Schwalbes line

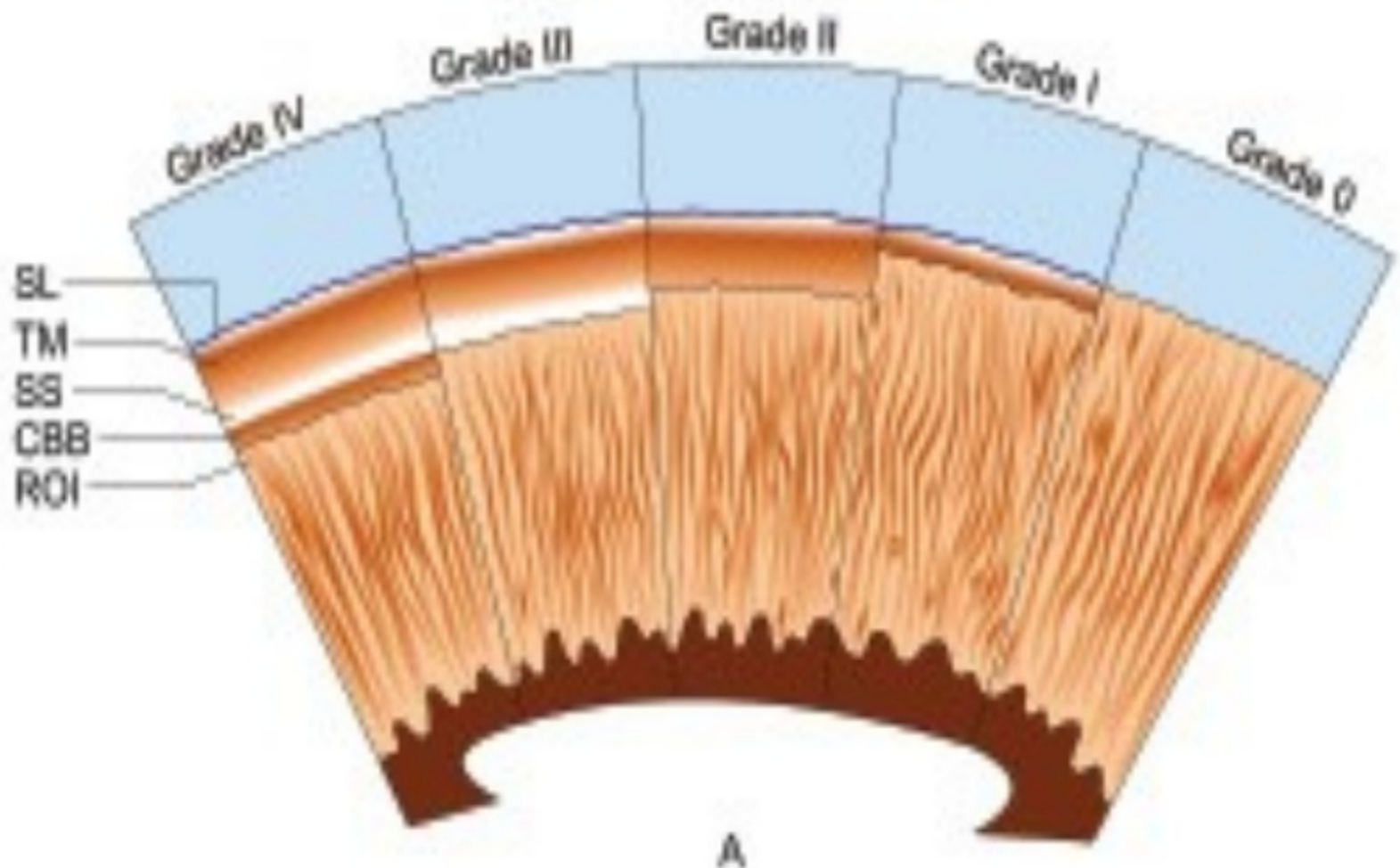
. Shaffer's system of grading the angle width

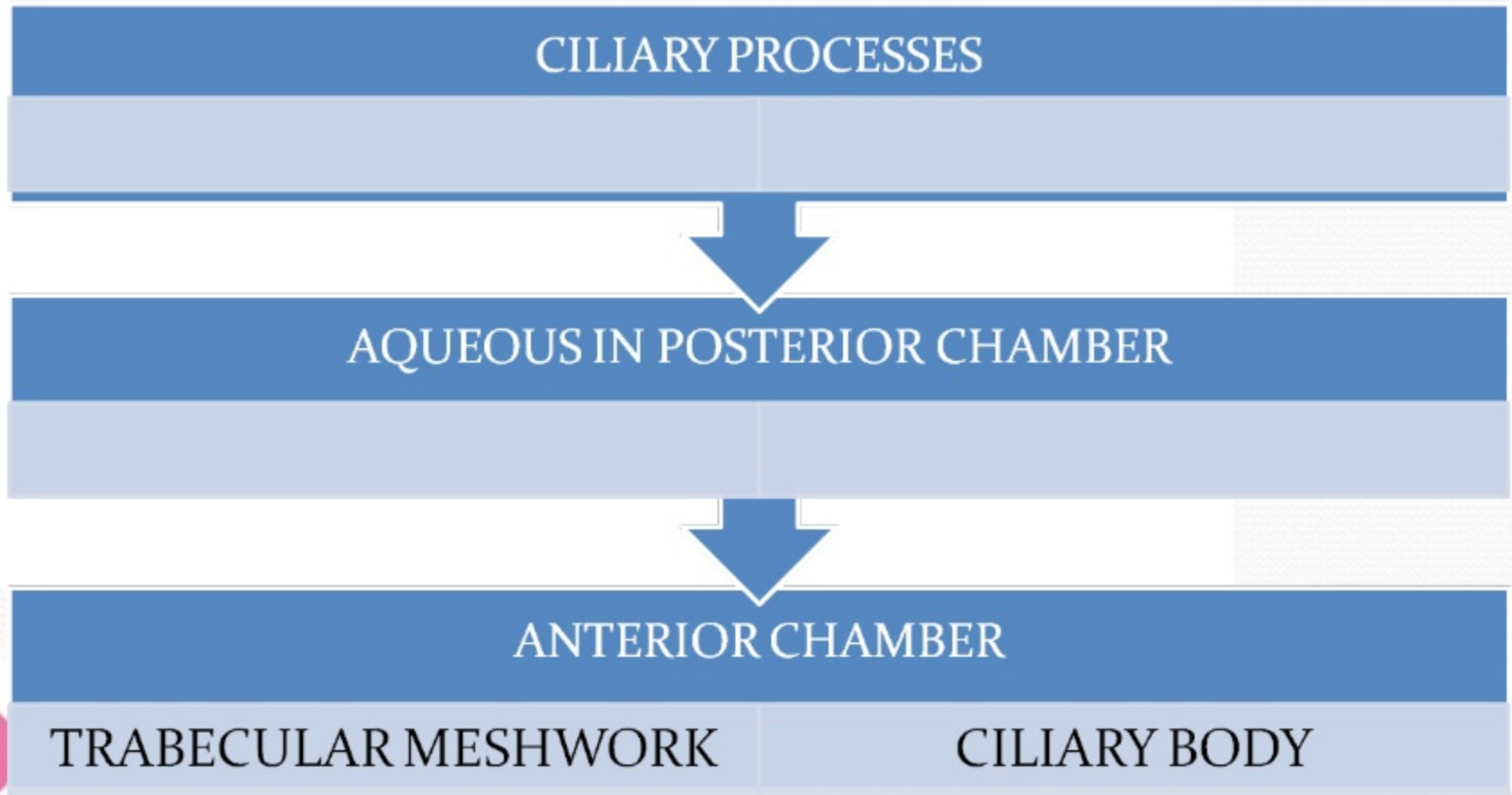
- ***Grade Angle width Configuration Chances of closure Structures visible on gonioscopy***
- IV 35-45° Wide open Nil SL, TM, SS, CBB
- III 20-35° Open angle Nil SL, TM, SS
- II 20° Moderately narrow Possible SL, TM
- I 10° Very narrow High SL only
- 0 0° Closed Closed None of the angle structures visible
- SL = Schwalbe's line, TM = Trabecular meshwork, SS = Scleral spur, CBB = Ciliary body band

Shaffer's system of grading the angle width



Shaffer's system of grading the angle width





SCHLEMM'S CANAL

SUPRACHOROIDAL SPACE



COLLECTOR CHANNELS, EPISCLERAL
VEINS

VENOUS CIRCULATION OF CILIARY
BODY, CHOROID, SCLERA

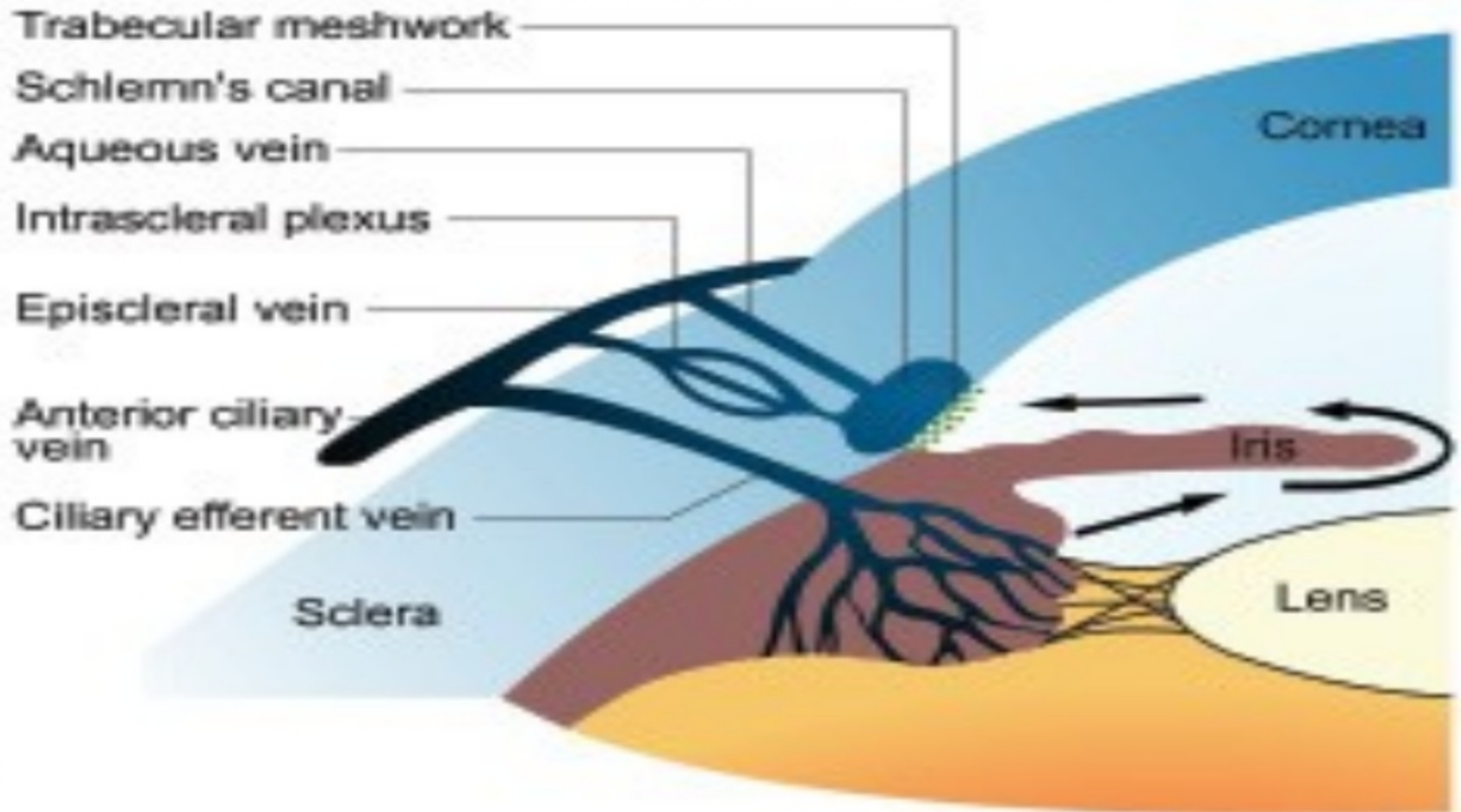


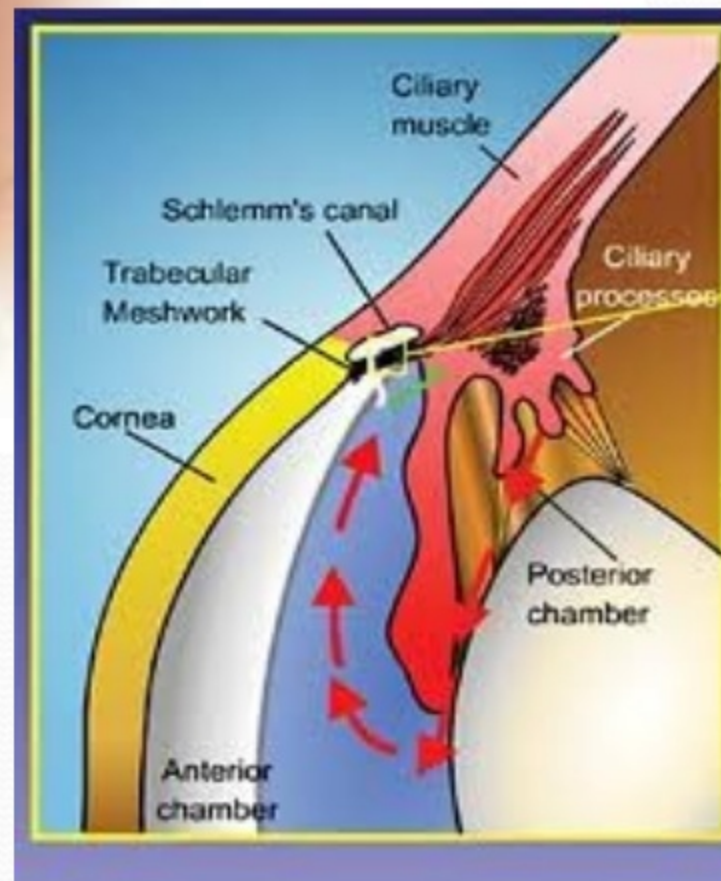
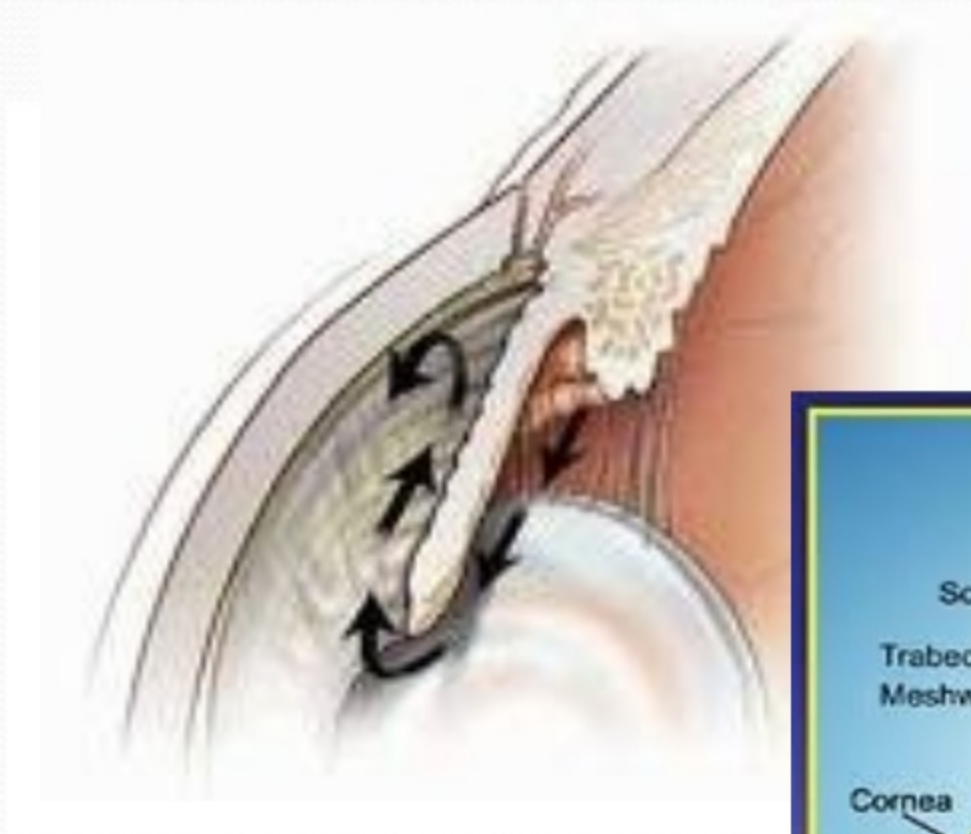
TRABECULAR OUTFLOW 90 %

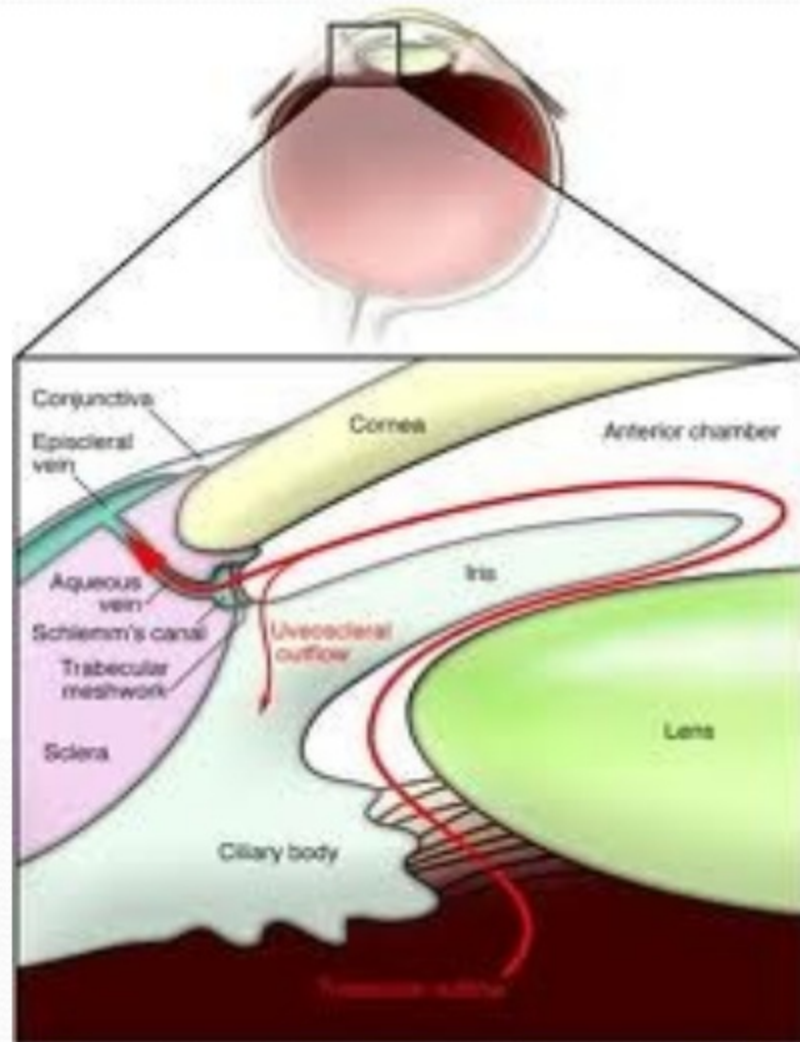
UVEOSCLERAL OUTFLOW 10 %

AQUEOUS OUTFLOW SYSTEM

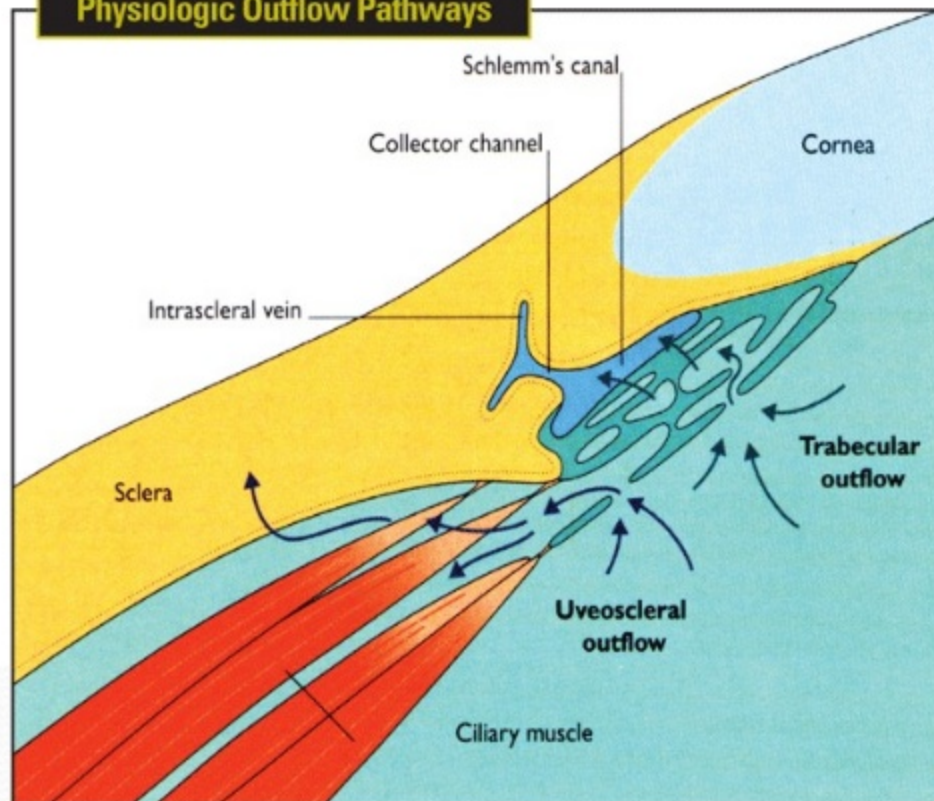
- IT INCLUDES
- TRABECULAR MESHWORK
- SCHLEMM'S CANAL
- COLLECTOR CHANNELS
- AQUEOUS VEINS
- EPISCLERAL VEINS







Physiologic Outflow Pathways



Enhancing outflow through existing physiologic pathways might be a more effective means to lower pressure than creating non-physiologic pathways.
(Figure from: Alm, Kaufman, et al. Uveoscleral Outflow: Biology and Clinical Aspects. Mosby-Wolfe Medical Communications, 1998. Used by permission.)

TRABECULAR MESHWORK

- IT IS SIEVE LIKE STRUCTURE THROUGH WHICH AQUEOUS HUMOUR LEAVES EYE

CONSIST OF 3 PORTIONS

1) UVEAL MESHWORK

- Innermost part of TM, extends from iris root and ciliary body to schwalbes line
- the arrangement of uveal trabecular bands create opening of 25 μ m to 75 μ m
- least resistance to flow

2) CORNEOSCLERAL MESHWORK

- larger middle portion ,extends from scleral spur to lateral wall of scleral sulcus

- opening 5 μ to 50 μ

Moderate resistance to flow